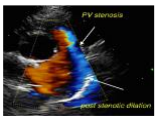
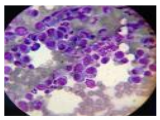
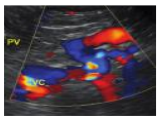

SonoPath.com
1-800-838-4268 info@sonopath.com

PATIENT
Frankie Cote

SPECIES
Canine

BREED
Golden Doodle

SEX
MN

Age
7 years

WEIGHT
44 kg

INTERPRETED BY
Remo Lobetti, BVSc, MMedVet (Med), PhD, Dipl. ECVIM

IMAGING PERFORMED BY
Dr Stan Gira

HOSPITAL NAME
Resolution Veterinary Ultrasound

REFERRING VET
Dr Stan Gira

INVOICE
303422

DATE
9/21/22

PRESENTING CLINICAL SIGNS

History: Diagnosed with digit SCC in Dec 2021, which was removed. Lame on the same leg 7 days ago – lytic bone lesion on digit #3.

Physical Examination: N/A.

Urinalysis: N/A.

CBC: N/A.

Serum Biochemistry: N/A.

Radiographic Findings: Normal thorax.

ULTRASONOGRAPHIC EXAMINATION OF THE ABDOMEN

Urinary System

Full urinary bladder with a normal thickness and appearance of the wall. Normal anechoic urine with no sediment or uroliths evident.

Normal trigone area, proximal urethra, and iliac blood vessels.

Normal iliac lymph nodes (1.7 cm). Ureters not visualized.

Normal renal size (left 6.7 cm right 6.8 cm), echogenic appearance, cortico-medullary differentiation, pelvis, and capsule.

Reproductive System

N/A.

Adrenal Glands

Normal shape, echogenic appearance, position, and size. Left 0.47/0.45 cm, right 0.63 cm.

Spleen

Normal size with a diffuse mottled echogenic appearance. Smooth homogenous parenchyma, regular curvilinear capsule, and normal vasculature. No evidence of inflammatory, neoplastic, infarction, or infiltrative changes noted.

Liver

Normal size, echogenic appearance, portal markings, and regular curvilinear capsule. Two focal parenchymal nodules – one with a hyperechogenic (0.8 cm) and the other one with a hypoechogenic appearance (0.7 cm). No masses evident. Full gall bladder containing normal anechoic bile. Normal thickness and appearance of the gall bladder wall. Normal bile duct.

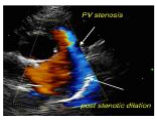
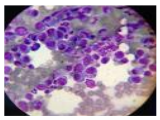
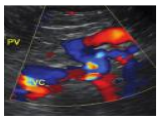

SonoPath.com
1-800-838-4268 info@sonopath.com

PATIENT

Frankie Cote

SPECIES

Canine

BREED

Golden Doodle

SEX

MN

Age

7 years

WEIGHT

44 kg

INTERPRETED BY

Remo Lobetti, BVSc, MMedVet (Med), PhD, Dipl. ECVIM

IMAGING PERFORMED BY

Dr Stan Gira

HOSPITAL NAME

Resolution Veterinary Ultrasound

REFERRING VET

Dr Stan Gira

INVOICE

303422

DATE

9/21/22

Gastrointestinal

Normal appearance of the stomach, duodenum, small intestine, ileo-cecal junction, and colon with no loss of layering, normal wall thickness and peristaltic activity, and no distension of the lumen.

Pancreas

Normal size (right 1.2 cm, left 1.2 cm) and echogenic appearance. Regular capsule. Normal echogenic appearance of the mesentery and fat surrounding the pancreas.

Free Abdomen

Normal mesenteric lymph nodes (1.3 cm).
No ascites.
Normal size of the aorta, caudal vena cava, and portal vein.

ULTRASONOGRAPHIC FINDINGS

Primary Findings:

- Liver nodules.
- Splenic hyperplasia.

Secondary Findings:

- None.

INTERPRETATION OF THE FINDINGS & FURTHER RECOMMENDATIONS

The two liver nodules are most likely incidental findings – nodular hyperplasia or organized hematoma, granuloma, or abscess; rather than metastatic foci.

The appearance of the spleen is consistent with hyperplasia with splenitis a differential diagnosis and neoplasia, an unlikely differential diagnosis.

Further assessment would be FNA cytology of the regional lymph node and possibly the spleen.

In a recent publication (Clinical Features and Outcome of 79 Dogs With Digital Squamous Cell Carcinoma Undergoing Treatment: A SIONCOV Observational Study, https://doi.org/10.3389/fvets.2021.645982), the majority of SCCs occurred in the front limbs (61%), bone lysis was frequently observed (92%), regional lymph node metastases was documented in 17% of dogs; and none of the dogs had evidence of distant metastasis.

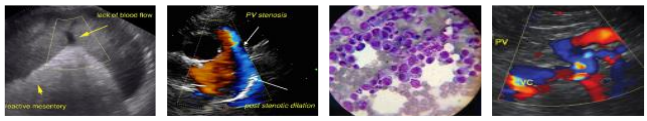

SonoPath.com
1-800-838-4268 info@sonopath.com

PATIENT

Frankie Cote

SPECIES

Canine

BREED

Golden Doodle

SEX

MN

Age

7 years

WEIGHT

44 kg

INTERPRETED BY

Remo Lobetti, BVSc, MMedVet (Med), PhD, Dipl. ECVIM

IMAGING PERFORMED BY

Dr Stan Gira

HOSPITAL NAME

Resolution Veterinary Ultrasound

REFERRING VET

Dr Stan Gira

INVOICE

303422

DATE

9/21/22

IMAGES

Liver

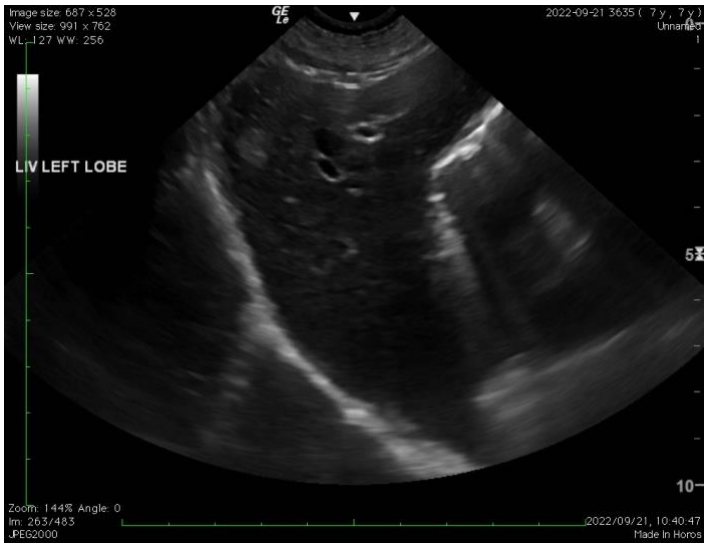

Spleen

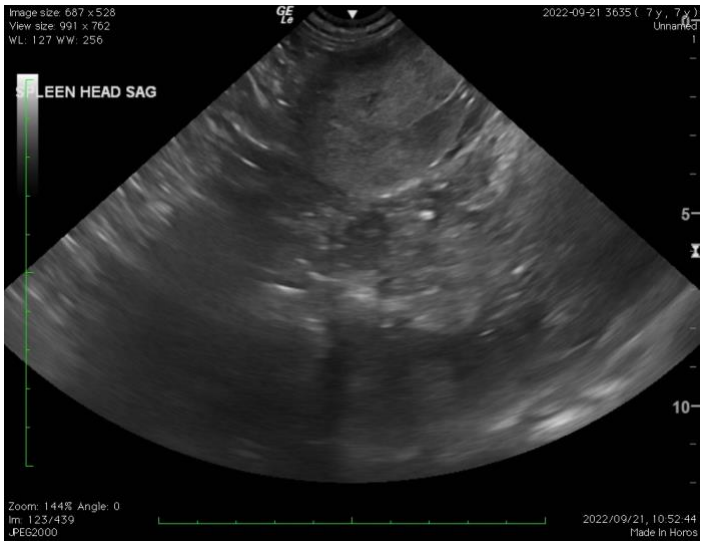

The information and recommendations provided are based on the images presented by the referring veterinarian. No evaluation can be communicated regarding pathology that was not visible in the image/video clips provided.

Thank you for this referral. If the clinical or image interpretation does not parallel your findings or if I can be of any further assistance, please contact me.

Remo Lobetti, BVSc, MMedVet (Med), PhD, Dipl. ECVIM (Internal Medicine)
rlobetti@mweb.co.za